European Journal of Radiology 85 (2016) 1893–1899

Contents lists available at ScienceDirect

European Journal of Radiology

journal homepage: www.elsevier.com/locate/ejrad

Dynamic CT myocardial perfusion imaging

Damiano Caruso (MD)[a,b], Marwen Eid (MD)[a], U. Joseph Schoepf (MD)[a,c,*], Kwang Nam Jin (MD)[a,d], Akos Varga-Szemes (MD, PhD)[a], Christian Tesche (MD)[a,e], Stefanie Mangold (MD)[a,f], Adam Spandorfer (MSc)[a], Andrea Laghi (MD)[b], Carlo N. De Cecco (MD, PhD)[a]

[a] Division of Cardiovascular Imaging, Department of Radiology and Radiological Science, Medical University of South Carolina, Charleston, SC, United States
[b] Department of Radiological Sciences, Oncological and Pathological Sciences, University of Rome "Sapienza", Latina, Italy
[c] Division of Cardiology, Department of Medicine, Medical University of South Carolina, Charleston, SC, United States
[d] Department of Radiology, Seoul Metropolitan Government-Seoul National University Boramae Medical Center, Seoul, Republic of Korea
[e] Department of Cardiology and Intensive Care Medicine, Heart Center Munich-Bogenhausen, Munich, Germany
[f] Department of Diagnostic and Interventional Radiology, University Hospital of Tuebingen, Tuebingen, Germany

ARTICLE INFO

Article history:
Received 25 April 2016
Received in revised form 21 July 2016
Accepted 24 July 2016

Keywords:
Myocardial perfusion imaging
Computed tomography
Dynamic CT myocardial perfusion
Coronary artery disease

ABSTRACT

Non-invasive cardiac imaging has rapidly evolved during the last decade due to advancements in CT based technologies. Coronary CT angiography has been shown to reliably assess coronary anatomy and detect high risk coronary artery disease. However, this technique is limited to anatomical assessment, thus non-invasive techniques for functional assessment of the heart are necessary. CT myocardial perfusion is a new CT based technique that provides functional assessment of the myocardium and allows for a comprehensive assessment of coronary artery disease with a single modality when combined with CTA. This review aims to discuss dynamic CT myocardial perfusion as a new technique in the assessment of CAD.

© 2016 Elsevier Ireland Ltd. All rights reserved.

1. Introduction

Recent advances in CT technology have allowed coronary CT angiography (CCTA) to play an increasingly important role in the non-invasive diagnosis of coronary artery disease (CAD) [1–3]. The accuracy of CCTA for CAD has been systematically analyzed with a reported high sensitivity (98%) and specificity (89%) and a negative predictive value of almost 100% [4]; thus, according to the appropriate use criteria, CCTA is now the first line modality for the exclusion of CAD in patients with low and intermediate risk profiles [4] (Fig. 1). Moreover, adding ECG-gated techniques has allowed CCTA to perform whole heart functional evaluations.

Although CCTA remains a robust morphological technique for coronary anatomy assessment and coronary plaque evaluation, it is limited in determining the hemodynamic significance of coronary stenoses (Fig. 2). Several studies highlighted that coronary stenosis assessment was not necessarily accurate in predicting myocardial ischemia, and that revascularization would be better guided by functional examination, as demonstrated by the FAME (Fractional Flow Reserve versus Angiography for Multivessel Evaluation) and COURAGE (Clinical Outcomes Utilizing Revascularization and Aggressive Drug Evaluation) trials [5,6]. In this regard, noninvasive functional techniques such as stress echocardiography, stress cardiac magnetic resonance (CMR) and single photon emission CT (SPECT) were shown to be accurate in detecting perfusion defects [7,8].

Thanks to recent technical innovations, non-invasive CCTA has raised this power shifting the interest from a morphological assessment, towards a more comprehensive morphological and functional evaluation [9]. In particular, recent technological advances in CT such as CT-myocardial perfusion imaging (MPI) allow this modality to perform a functional analysis of the heart and shows promise in accurately detecting hemodynamically significant coronary artery stenosis [9,10]. Combining CT-MPI with CCTA could establish CT as a standalone modality for comprehensive assessment of CAD and direct assessment of myocardial ischemia in a single session.

Abbreviations: CAD, coronary artery disease; CCTA, coronary CT angiography; CMR, cardiac magnetic resonance; CT-MPI, computed tomography myocardial perfusion imaging; DSE, dobutamine stress echocardiography; MPI, myocardial perfusion imaging; SPECT, single-photon emission computed tomography.

* Corresponding author at: Department of Radiology and Radiological Science, Medical University of South Carolina, Ashley River Tower, MSC 226, 25 Courtenay Drive, Charleston, SC 29425, United States.
E-mail address: schoepf@musc.edu (U.J. Schoepf).

http://dx.doi.org/10.1016/j.ejrad.2016.07.017
0720-048X/© 2016 Elsevier Ireland Ltd. All rights reserved.

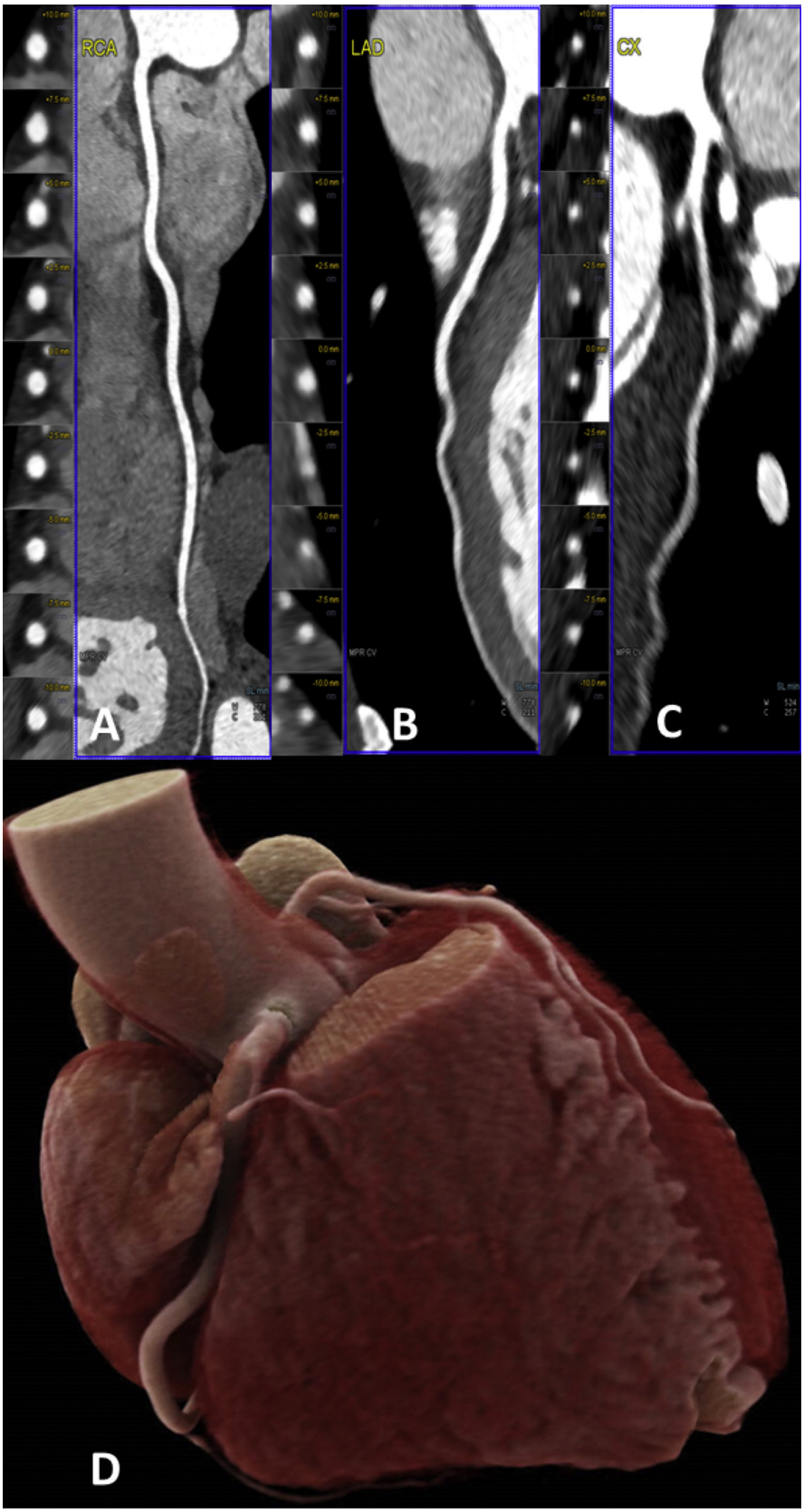

Fig. 1. 55 year old patient smoker with intermediate risk profile complaining of chest pain. A triple rule out study was performed. Curved mutliplanar reconstruction of the RCA (A), LAD (B) and Circumflex (C) arteries showing patent vessels with no stenosis. Cinematic rendering reconstruction (Siemens Healtcare, not for clinical use) of the heart of the same patient (D).

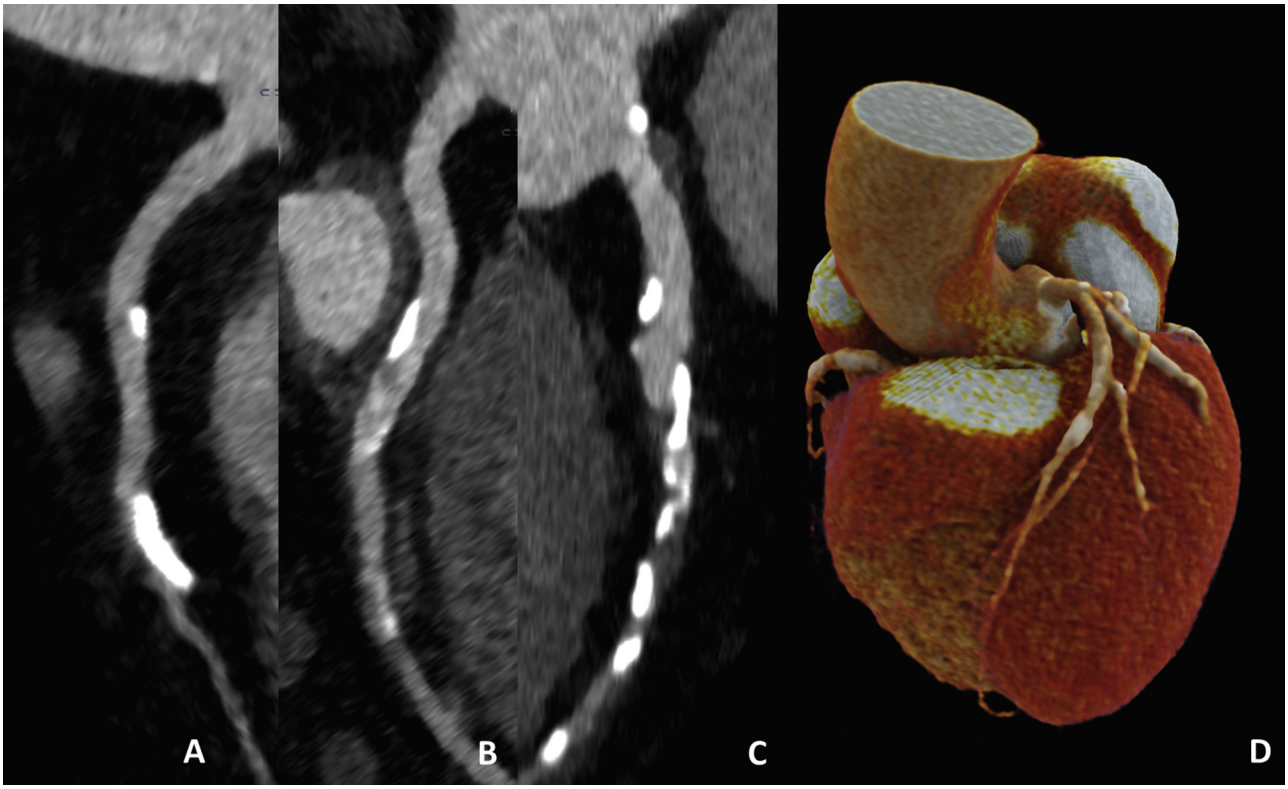

Fig. 2. 60 year old patient who presented with chest patient and was referred for a CCTA. Curved mutliplanar reconstruction of the RCA (A), LAD (B) and Circumflex (C) arteries showing multiple calcified plaques. Cinematic rendering reconstruction (Siemens Healtcare, not for clinical use) of the heart of the same patient (D) with excellent representation of the calcified plaques.

CT myocardial perfusion techniques are mainly divided in two major approaches: static CT myocardial perfusion which can further be divided into single energy [11] and dual energy techniques [12], and dynamic CT myocardial perfusion [13–15]. The aim of this article is to provide an overview of dynamic CT myocardial perfusion imaging.

2. Myocardial perfusion imaging

Many non-invasive techniques allow for evaluation of myocardial perfusion: stress echocardiography and stress CMR, as well as PET- and SPECT-MPI. Although dobutamine stress echocardiography (DSE) could provide diagnostic information about abnormal ventricular wall motion in case of ischemia, dobutamine stress CMR was found to be superior to DSE in terms of specificity (87.5% vs 72.9%), negative predictive value (80.8% vs 67.3%) and overall diagnostic accuracy (80.4% vs 72%) [16]. Moreover, adenosine stress perfusion CMR was reported to have a sensitivity of 88.7% and a specificity of 83.5% for the detection of CAD when compared to invasive coronary angiography (ICA), as reported in the CE-MARC trial [17], and higher sensitivity compared to SPECT (75% vs 59%; $p = 0.03$), as reported in the MR-IMPACT II trial [18]. Nuclear imaging such as PET and SPECT are also robust modalities for the diagnosis of CAD. PET-MPI has demonstrated higher sensitivity (92.6% vs 88.3%) and specificity (81.3% vs 76.0%) for CAD compared to SPECT-MPI, as recently shown in a large meta-analysis [19]. PET-MPI is considered the modality of choice for myocardial blood flow quantification particularly when ^{13}N-ammonia is used. However, this approach has been applied mainly in a research setting and not in clinical practice, whereas CT-MPI could be used routinely if its validity is affirmed.

Despite the fact that these techniques are well validated, none of them provide an anatomic evaluation of coronary arteries and a subsequent hemodynamic evaluation of coronary stenosis together with a functional assessment of the heart. This problem is addressed by state of the art CT technology. Thanks to its ability to evaluate all three bases of CAD (i.e. coronary artery stenosis, ventricular function and myocardial perfusion), CCTA is establishing itself as a possible stand-alone modality for the evaluation of patients with suspected CAD within a single session [12].

3. Stress agents

Perfusion imaging can identify reduced myocardial blood flow. MPI can be performed either at rest, at stress, or both. A hyperemic myocardium is normally induced via coronary artery vasodilation after pharmacological stress. Different stress agents such as adenosine, regadenoson, dobutamine and dipyridamole are used for stress myocardial perfusion, each with their own advantages and disadvantages [9].

Adenosine vasodilates the coronary arteries directly via the adenosine A1 receptors. It is administered in a continuous dose of 140 μg/kg/min for at least two minutes, as it has a very short half-life of a few seconds, resulting in increased heart rate by 10–20 beats per minute.

Regadenoson works as a selective A2A receptor agonist. This gives it the particular advantage of being usable in patients with asthma or chronic obstructive pulmonary disease, since it causes less systemic side effects. Due to its longer half-life, regadenoson can be administered in a single dose with peak vasodilation after 2–4 min, allowing for more time efficient CT studies. Both agents can cause moderate complications such as ventricular tachycardia and transient atrial-ventricular block in less than 1% of patients, although in rarer cases acute myocardial infarction and even death were reported.

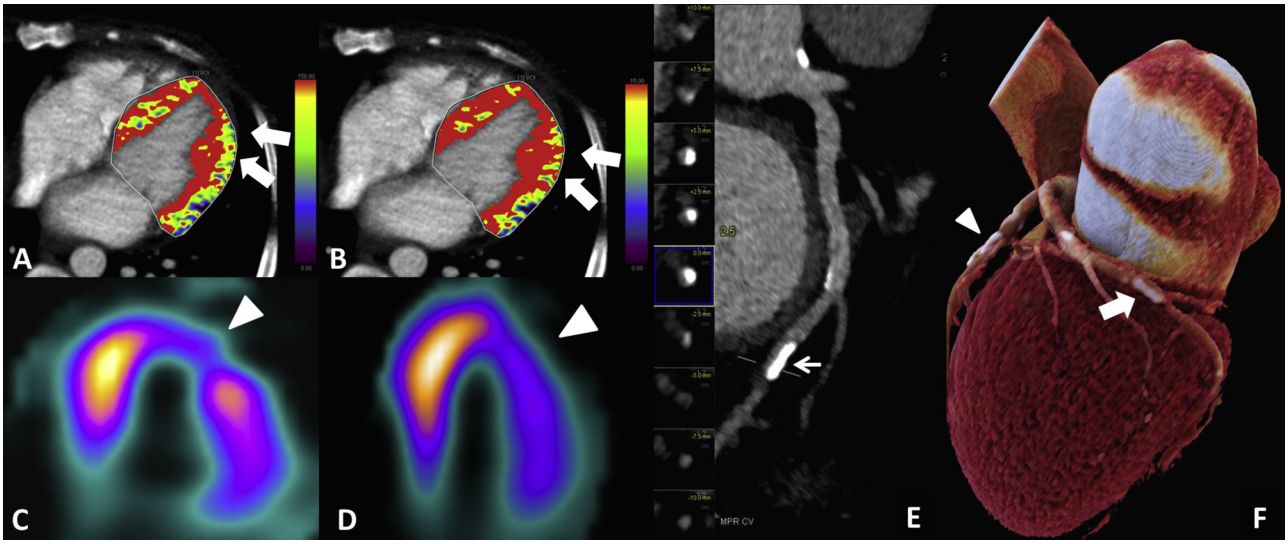

Fig. 3. 59 year old female patient complaining of chest pain episodes lasting up to 30 min and radiating to left shoulder. The Dynamic CT MPI with a color coded map of myocardial blood flow (A) shows a decreased blood flow in the anterolateral wall of the left ventricle (white arrows). The Dynamic CT MPI with a color coded map of myocardial blood volume (B) shows a decreased volume in the anterolateral wall of the left ventricle (white arrows).
SPECT imaging of the heart in rest (C) and stress (D) phases shows a fixed perfusion defect in the anterolateral wall region, involving approximately 20–25% of the LV myocardium (white arrowheads). Dynamic CT MPI gives the ability to generate time attenuation curves of the myocardium (E).

Dipyridamole and dobutamine are not commonly used. Dipyridamole acts as an indirect artery vasodilator by blocking adenosine cellular uptake, thus increasing its endogenous levels. It is usually administered in a continuous infusion of 0.56 mg/kg/min over 4–6 min. Since it has a longer half-life than adenosine, an adenosine receptor antagonist, called aminophylline, is usually needed to reverse its effect. Dobutamine, on the other hand, acts directly on myocardial β-1 receptors, increasing myocardial contractility and thus oxygen consumption.

4. Dynamic CT myocardial perfusion

4.1. Backgrounds and general considerations

CT-myocardial perfusion imaging (CT-MPI) studies the distribution of contrast media during its initial pass through the myocardium. Since myocardial blood supply determines contrast distribution, hypoattenuating areas containing a reduced amount of contrast media indicate possible myocardial perfusion defects. To perform a comprehensive CT myocardial perfusion study, both rest phase and stress phase acquisitions are necessary [7]. This approach allows for distinguishing reversible lesions that appear hypoattenuating in the stress phase only, rather than irreversible ischemia documented as a persisting perfusion defect also seen at rest [7]. Different workflows have been described to perform a myocardial perfusion study. A rest/stress protocol provides complete information about coronary arteries before the functional examination and could reduce additional acquisitions and unnecessary radiation exposure. However, a possible contamination of contrast media during the stress phase is considered the main drawback of this approach that could cover ischemic regions, thus it is recommended to wait 10–20 min between the two phases. Starting with the stress phase would avoid contrast material contamination from the rest phase, thus allowing maximal contrast difference between the normal and ischemic myocardium. However, a drawback to this technique is reduced image quality of the subsequent rest phase due to an elevated heart rate. In addition, an optional delayed phase approximately 10 min after contrast administration can also be performed to detect myocardial scar as an enhancing region.

4.2. Technical aspects

Compared to static CT-MPI, which is based on a static evaluation of contrast medium distribution in the myocardium during early arterial attenuation, dynamic CT-MPI uses serial acquisitions of the myocardium through the whole cardiac cycle to track the kinetics of contrast media distribution during the initial pass, arterial phase and microcirculation. It usually takes up to 32 s after the administration of contrast material for differences between normal and abnormal myocardium to show.

For a dynamic CT perfusion imaging study to be clinically feasible, greater volume coverage of the left ventricle must be attained. This was recently accomplished with the introduction of single-tube multidetector CT scanners with 256 or 320 detector rows, which allow full heart coverage with a stationary table or by using the shuttle mode in second generation Dual Source CT scanners. This modality allowed the table to shuttle back and forth between two alternating adjacent anatomic positions, extending the anatomic coverage from 38 mm to 73 [15]. Currently, third generation DECT scanners have coverage of 105 mm, allowing whole heart imaging even in dilated hearts.

The optimal phase for image acquisition in Dynamic CT-MPI is the end of the systolic phase (250 ms after the R peak) [15]. Two main advantages are reported. First, during this phase myocardial wall is at maximal thickness and the apical-basal length is shorter, allowing the whole heart to be imaged. Second, the systolic phase has a constant duration of approximately 200 ms, regardless of heart rate. Consequently, the amount of contrast medium needed for this phase is lower, thus reducing beam-hardening artifacts. Usually the diagnosis of fixed perfusion defect is made when hypoattenuation lasted for more than 6 heartbeats under stress and when delayed enhancement is present [13].

4.3. Data analysis techniques

The main advantage of the dynamic technique is the possibility of direct quantification of myocardial blood flow (MBF), MBF ratio, and myocardial blood volume (MBV) via mathematical models applied to TACs [20] (Figs. 3 and 4). There are two major data

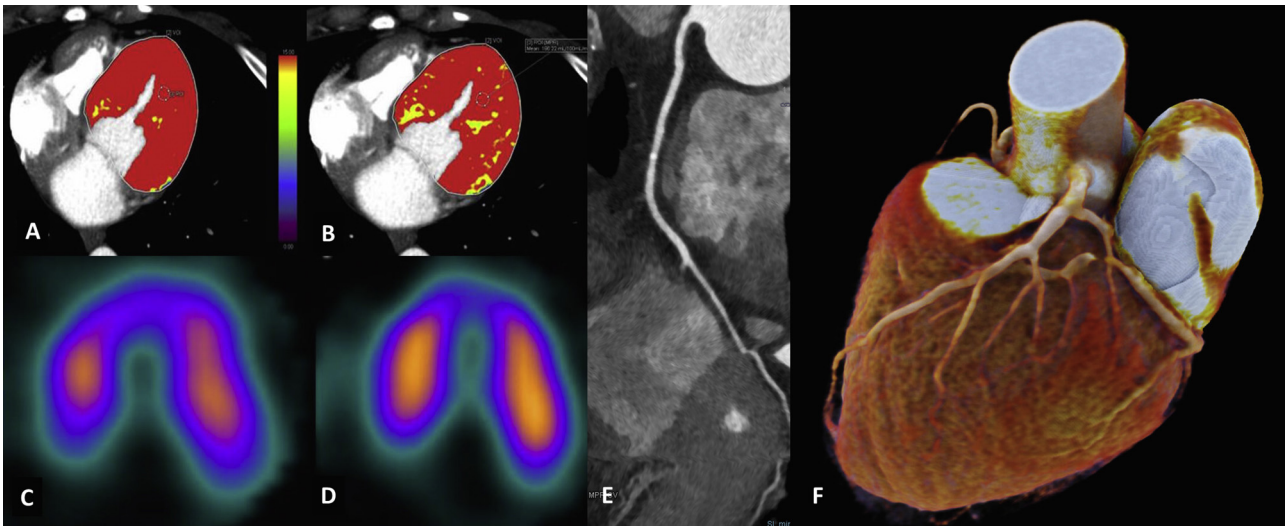

Fig. 4. 49 year old patient with intermediate cardiovascular risk who presented with chest pain. The dynamic CT MPI was performed with color coded maps of myocardial blood flow (A) and myocardial blood volume (B). SPECT imaging in both rest phase (C) and stress phase (D) shows normal myocardial perfusion. The axial view (E) shows a hypertrophic left ventricle (white arrows). The time attenuation curve of the myocardium is derived from the dynamic CT MPI acquisition (F).

analysis methods for Dynamic CT-MPI, a semi-quantitative method and a quantitative method.

In the semi-quantitative method the mean attenuation of a region of interest of the myocardium is assessed over time, resulting in time attenuation curves, which are used to extract blood flow related parameters, such as peak enhancement, time to peak, attenuation upslope and area under the curve. The most commonly used method for a semi-quantitative analysis is the upslope method [13]. One major advantage of this technique is the reduction in radiation dose since only the upslope is required for data acquisition.

The quantitative method is based on a mathematical model, which assesses perfusion parameters via blood flow input and output functions analysis and evaluation of contrast agent extraction rate from the intravascular rate (Fig. 5). The most commonly used models are based on deconvolution methods already used in CMR studies and adapted for CT [13,21]. Moreover, semi-automated software is now available for quantitative analysis, which shows similar accuracy to manual analysis for both MBF (142.85 vs 142.39 mL/100 mL/min, $p = 0.50$) and MBV (18.6 vs 18.8 mL/100 mL, $p = 0.60$), but with reduced analysis times (16.5 ± 3.7 min for the semi-automated method vs 49.1 ± 11.2 min for the manual analysis, $p < 0.001$) as reported by Ebersberger et al. [20]. Recently Wichmann et al. reported MBF ratio to be superior to absolute MBF in the discrimination of coronary artery stenosis (area under curve = 0.882, $p = 0.0022$) [22].

4.4. Clinical significance

A limited number of studies were published as represented in Table 1. Huber et al. compared Dynamic CT-MPI to invasive coronary angiography for coronary stenosis and reported a MBF sensitivity, specificity, PPV and NPV values respectively of 75.9%, 100%, 100% and 90.5% respectively by using a semi-quantitative analysis [23]. Recently, by using ICA as a gold standard Baxa et al. reported a higher specificity in asymptomatic population for stress myocardial perfusion and CTA compared to CTA alone (per-segment: specificity 96% vs 68%, $p = 0.02$; per-vessel: specificity 95% vs. 75%, $p = 0.012$) [24]. Likewise, Magalhaes et al. reported higher specificity (0.73 vs. 0.54) and overall diagnostic accuracy (0.75 vs 0.69, $p = 0.004$) by using a combination of CTA and CT-MPI compared to only CTA in detecting flow-limiting stenosis in CORE320 trial [25], whereas Greif et al. also reported high values of sensitivity (95%) and negative predictive value (98%) by using Dynamic CT-MPI for the diagnosis of hemodynamically significant CAD [26]. Moreover, the authors reported a cut-off value of 78 mL/100 mL/min for differentiating hemodynamically significant from non-significant lesions [26], in accordance to Bamberg et al. who had previously proposed a cut-off value of 75 mL/100 mL/min [21]. Similarly, Rossi et al. reported a cut-off value of 78 mL/100 mL/min [27].

Some studies have also evaluated Dynamic CT-MPI compared to different non-invasive modalities. In a study that compared stress dynamic CT myocardial perfusion with CMR, Bastarrika et al. found values for sensitivity, specificity, positive and negative predictive of 86.1%, 98.2%, 93.9% and 95.7% respectively [13], as well as Bamberg et al. reported, comparing Dynamic CT-MPI and CMR, showing a sensitivity, specificity, positive and negative predictive values of 77.8%, 75.41%, 50.6% and 91.3% respectively [28]. CMR-MPI is routinely applied in clinical practice, however quantification of myocardial blood flow is complex considering the non-linear relationship between gadolinium concentration and MR signal. As a result, only qualitative assessment is performed routinely [28]. On the other hand, CT-MPI could provide more accurate and reliable results due to the possibility of direct quantification of myocardial blood flow and the higher spatial resolution.

Ho et al. evaluated stress Dynamic CT-MPI on a 128 slice DECT using dipyridamole in comparison to nuclear myocardial perfusion with a reported sensitivity, specificity, positive and negative predictive value was 83%, 78%, 79% and 82% respectively [29]. Wang et al. also compared Dynamic CT-MPI to SPECT finding sensitivity, specificity, PPV, and NPV values of 82%, 92%, 55% and 98% respectively [8]. In a study by Weininger et al. adenosine stress dynamic myocardial perfusion CT was compared to SPECT and MRI and was found to have comparable results to both modalities [15].

Global evaluation of myocardial perfusion can be particularly useful in the evaluation of multivessell disease. In a recent multicenter study, Meinel et al. manually analyzed myocardial perfusion across the entire volume of left ventricle in 146 patients reporting a cutoff value of 105 mL/100 mL/min or less for MBF and 15 mL/100 mL or less for MBV with a sensitivity and specificity for three-vessel perfusion defects of 100% and 89% for MBF and 100% and 96% for MBV, respectively [14]. Recently by using semiautomated software for the evaluation of global myocardial perfusion, Wichmann et al. reported a sensitivity and NPV of 100% with a cut-

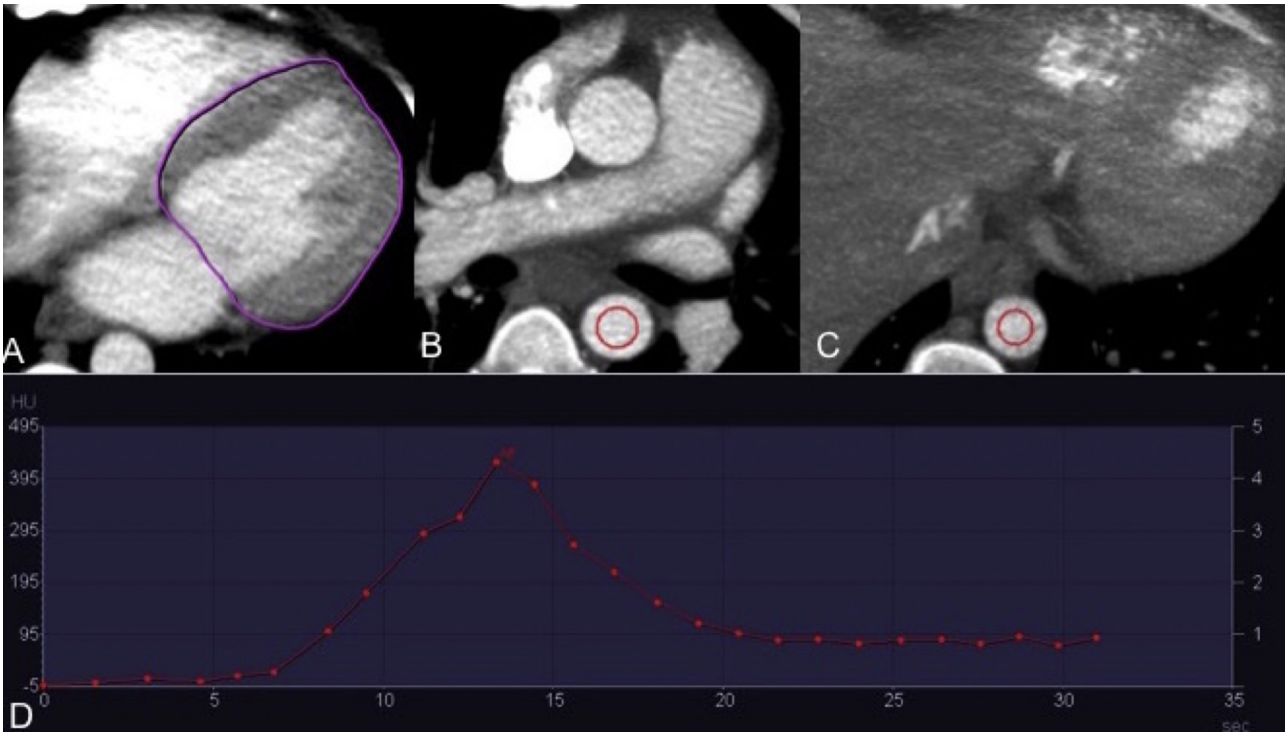

Fig. 5. 59 year old female patient complaining of chest pain episodes radiating to left shoulder. This image shows the post processing steps in the dynamic myocardial perfusion workflow, starting with myocardium segmentation (A), then defining the cranial and caudal arteries via a ROI (B, C), generating a TAC showing the arterial input function.

Table 1
Dynamic CT Myocardial Perfusion Studies.

Study	Year	Patient Population	CT Technology	Average Radiation Dose (mSv)	Reference Standard Technique	Sensitivity (%)	Specificity (%)	NPV (%)	PPV (%)	Analysis Basis
Wichmann et al. [30]	2016	71	2nd generation DSCT	8.2	Visual assessment	100	88	100	43	Segmental
Baxa et al. [24]	2015	54	2nd generation DSCT	8.9	ICA	97	95	98	95	Vessel
						98	96	98	96	Segmental
Magalhaes et al. [25]	2015	381	320 Row MDCT	–	ICA + SPECT MPI	58	86	87	55	Vessel
Bamberg et al. [28]	2014	31	2nd generation DSCT	11.1	Cardiac MRI	100	75	100	92	Vessel
						78	75	91	51	Segmental
Rossi et al. [27]	2013	80	2nd generation DSCT	9.4	ICA	88	90	98	77	Vessel
Huber et al. [23]	2013	32	256 Row MDCT	9.5	ICA	76	100	90	100	Vessel
Greif et al. [26]	2013	65	2nd generation DSCT	9.7	ICA	95	74	98	50	Vessel
Weininger et al. [15]	2012	20	2nd generation DSCT	12.8	Cardiac MRI	86	98	96	94	Segmental
Wang et al. [8]	2012	30	2nd generation DSCT	9.5	SPECT and ICA	85	92	98	55	Segmental
Bamberg et al. [21]	2011	33	2nd generation DSCT	10	ICA	93	87	93	75	Vessel
Ho et al. [29]	2010	35	2nd generation DSCT	18.2	SPECT and ICA	83	78	82	79	Segmental
Bastarrika et al. [13]	2010	10	2nd generation DSCT	18.8	Cardiac MRI	86	98	96	94	Segmental

off value of ≤88 mL/100 mL/min for MBF and of ≤15 mL/100 mL for MBV [30].

4.5. Limitations

There are 3 major limitations for Dynamic CT-MPI. Firstly, the most important limitation is the high radiation doses required when using this technique. A combined rest and stress myocardial perfusion study can reach a radiation dose of 18.2 mSv [29]. Of note however, radiation doses achieved with CT myocardial perfusion imaging are still lower than those with nuclear imaging and new methods are being developed to reduce radiation exposure. The reduction of the kV levels and the application of iterative reconstruction techniques were shown to reduce radiation doses and

the application of these techniques to a rest/stress study managed to achieve radiation doses of 2.5 mSv. Secondly, dynamic CT-MPI alone cannot provide a morphological assessment of the coronary arteries. Consequently, a dedicated CCTA study is needed in addition to the perfusion study for a full comprehensive assessment of CAD with CT, which further increases the radiation exposure. However, again with the implementation of state of the art scanner the CCTA study can be performed with low radiation dose ranging from <1 mSv up to 3 mSv according to the acquisition technique used [2]. Lastly, whole heart scanning necessitates a relatively long breath hold of more than 30 s, which can be difficult in patients with breathing problems.

5. Conclusion

CT myocardial perfusion is growing as a new technique that provides a functional assessment of the myocardium along with a comprehensive evaluation of coronary artery disease within a single modality. The addition of dynamic CT myocardial perfusion to standard coronary CTA can provide insightful information on significant coronary stenosis, particularly for hemodynamically relevant lesions, which may be helpful for patient management. Recently, CT myocardial perfusion studies have been performed with promising results; however these studies were limited by small patient populations. Thus, further investigations are recommended to define and validate dynamic CT perfusion due to its extensive application potential.

Conflict of interest

Dr. Schoepf is a consultant for and/or receives research support from Astellas, Bayer, Bracco, GE, Guerbet, Medrad, and Siemens Healthcare.

References

[1] U.J. Schoepf, J.C. Carr, Coronary artery disease and the myocardial ischemic cascade: state-of-the-art computed tomography and MR imaging, Radiol. Clin. N. Am. 53 (2015) xv–xvi.

[2] C.N. De Cecco, F.G. Meinel, S.A. Chiaramida, P. Costello, F. Bamberg, U.J. Schoepf, Coronary artery computed tomography scanning, Circulation 129 (2014) 1341–1345.

[3] C. Becker, M. Schatzl, H. Feist, A. Bauml, U.J. Schopf, G. Michalski, et al., Assessment of the effective dose for routine protocols in conventional CT, electron beam CT and coronary angiography, Rofo 170 (1999) 99–104.

[4] J.E. Jacobs, L.M. Boxt, B. Desjardins, E.K. Fishman, P.A. Larson, J. Schoepf, ACR practice guideline for the performance and interpretation of cardiac computed tomography (CT), J. Am. Coll. Radiol. 3 (2006) 677–685.

[5] N.H. Pijls, W.F. Fearon, P.A. Tonino, U. Siebert, F. Ikeno, B. Bornschein, et al., Fractional flow reserve versus angiography for guiding percutaneous coronary intervention in patients with multivessel coronary artery disease: 2-year follow-up of the FAME (fractional flow reserve versus angiography for multivessel evaluation) study, J. Am. Coll. Cardiol. 56 (2010) 177–184.

[6] L.J. Shaw, D.S. Berman, D.J. Maron, G.B. Mancini, S.W. Hayes, P.M. Hartigan, et al., Optimal medical therapy with or without percutaneous coronary intervention to reduce ischemic burden: results from the clinical outcomes utilizing revascularization and aggressive drug evaluation (COURAGE) trial nuclear substudy, Circulation 117 (2008) 1283–1291.

[7] F.G. Meinel, C.N. De Cecco, U.J. Schoepf, J.W. Nance Jr., J.R. Silverman, B.A. Flowers, et al., First-arterial-pass dual-energy CT for assessment of myocardial blood supply: do we need rest, stress, and delayed acquisition? Comparison with SPECT, Radiology 270 (2014) 708–716.

[8] Y. Wang, L. Qin, X. Shi, Y. Zeng, H. Jing, U.J. Schoepf, et al., Adenosine-stress dynamic myocardial perfusion imaging with second-generation dual-source CT: comparison with conventional catheter coronary angiography and SPECT nuclear myocardial perfusion imaging, Am. J. Roentgenol. 198 (2012) 521–529.

[9] C.N. De Cecco, A. Varga-Szemes, F.G. Meinel, M. Renker, U.J. Schoepf, Beyond stenosis detection: computed tomography approaches for determining the functional relevance of coronary artery disease, Radiol. Clin. N. Am. 53 (2015) 317–334.

[10] A. Varga-Szemes, F.G. Meinel, C.N. De Cecco, S.R. Fuller, R.R. Bayer 2nd, U.J. Schoepf, CT myocardial perfusion imaging, Am. J. Roentgenol. 204 (2015) 487–497.

[11] A.M. Bucher, C.N. De Cecco, U.J. Schoepf, R. Wang, F.G. Meinel, S.R. Binukrishnan, et al., Cardiac CT for myocardial ischaemia detection and characterization—comparative analysis, Br. J. Radiol. 87 (2014) 20140159.

[12] R. Vliegenthart, G.J. Pelgrim, U. Ebersberger, G.W. Rowe, M. Oudkerk, U.J. Schoepf, Dual-energy CT of the heart, Am. J. Roentgenol. 199 (2012) S54–63.

[13] G. Bastarrika, L. Ramos-Duran, M.A. Rosenblum, D.K. Kang, G.W. Rowe, U.J. Schoepf, Adenosine-stress dynamic myocardial CT perfusion imaging: initial clinical experience, Invest. Radiol. 45 (2010) 306–313.

[14] F.G. Meinel, U. Ebersberger, U.J. Schoepf, G.G. Lo, Y.H. Choe, Y. Wang, et al., Global quantification of left ventricular myocardial perfusion at dynamic CT: feasibility in a multicenter patient population, Am. J. Roentgenol. 203 (2014) W174–80.

[15] M. Weininger, U.J. Schoepf, A. Ramachandra, C. Fink, G.W. Rowe, P. Costello, et al., Adenosine-stress dynamic real-time myocardial perfusion CT and adenosine-stress first-pass dual-energy myocardial perfusion CT for the assessment of acute chest pain: initial results, Eur. J. Radiol. 81 (2012) 3703–3710.

[16] I. Mordi, T. Stanton, D. Carrick, J. McClure, K. Oldroyd, C. Berry, et al., Comprehensive dobutamine stress CMR versus echocardiography in LBBB and suspected coronary artery disease, JACC Cardiovasc. Imaging 7 (2014) 490–498.

[17] J.P. Greenwood, M. Motwani, N. Maredia, J.M. Brown, C.C. Everett, J. Nixon, et al., Comparison of cardiovascular magnetic resonance and single-photon emission computed tomography in women with suspected coronary artery disease from the clinical evaluation of magnetic resonance imaging in coronary heart disease (CE-MARC) trial, Circulation 129 (2014) 1129–1138.

[18] J. Schwitter, C.M. Wacker, N. Wilke, N. Al-Saadi, E. Sauer, K. Huettle, et al., MR-IMPACT II: magnetic resonance imaging for myocardial perfusion assessment in coronary artery disease trial: perfusion-cardiac magnetic resonance vs single-photon emission computed tomography for the detection of coronary artery disease: a comparative multicentre, multivendor trial, Eur. Heart J. 34 (2013) 775–781.

[19] M.W. Parker, A. Iskandar, B. Limone, A. Perugini, H. Kim, C. Jones, et al., Diagnostic accuracy of cardiac positron emission tomography versus single photon emission computed tomography for coronary artery disease: a bivariate meta-analysis, Circ. Cardiovasc. Imaging 5 (2012) 700–707.

[20] U. Ebersberger, R.P. Marcus, U.J. Schoepf, G.G. Lo, Y. Wang, P. Blanke, et al., Dynamic CT myocardial perfusion imaging: performance of 3D semi-automated evaluation software, Eur. Radiol. 24 (2014) 191–199.

[21] F. Bamberg, A. Becker, F. Schwarz, R.P. Marcus, M. Greif, F. von Ziegler, et al., Detection of hemodynamically significant coronary artery stenosis: incremental diagnostic value of dynamic CT-based myocardial perfusion imaging, Radiology 260 (2011) 689–698.

[22] J.L. Wichmann, F.G. Meinel, U.J. Schoepf, G.G. Lo, Y.H. Choe, Y. Wang, et al., Absolute versus relative myocardial blood flow by dynamic CT myocardial perfusion imaging in patients with anatomic Coronary artery disease, Am. J. Roentgenol. 205 (2015) W67–W72.

[23] A.M. Huber, V. Leber, B.M. Gramer, D. Muenzel, A. Leber, J. Rieber, et al., Myocardium: dynamic versus single-shot CT perfusion imaging, Radiology 269 (2013) 378–386.

[24] J. Baxa, M. Hromadka, J. Sedivy, L. Stepankova, J. Molacek, B. Schmidt, et al., Regadenoson-stress dynamic myocardial perfusion improves diagnostic performance of CT angiography in assessment of intermediate coronary artery stenosis in asymptomatic patients, BioMed Res. Int. 2015 (2015) 105629.

[25] T.A. Magalhaes, S. Kishi, R.T. George, A. Arbab-Zadeh, A.L. Vavere, C. Cox, et al., Combined coronary angiography and myocardial perfusion by computed tomography in the identification of flow-limiting stenosi—the CORE320 study: an integrated analysis of CT coronary angiography and myocardial perfusion, J. Cardiovasc. Comput. Tomogr. 9 (2015) 438–445.

[26] M. Greif, F. von Ziegler, F. Bamberg, J. Tittus, F. Schwarz, M. D'Anastasi, et al., CT stress perfusion imaging for detection of haemodynamically relevant coronary stenosis as defined by FFR, Heart 99 (2013) 1004–1011.

[27] A. Rossi, A. Uitterdijk, M. Dijkshoorn, E. Klotz, A. Dharampal, M. van Straten, et al., Quantification of myocardial blood flow by adenosine-stress CT perfusion imaging in pigs during various degrees of stenosis correlates well with coronary artery blood flow and fractional flow reserve, Eur. Heart J. Cardiovasc. Imaging 14 (2013) 331–338.

[28] F. Bamberg, R.P. Marcus, A. Becker, K. Hildebrandt, K. Bauner, F. Schwarz, et al., Dynamic myocardial CT perfusion imaging for evaluation of myocardial ischemia as determined by MR imaging, JACC Cardiovasc. Imaging 7 (2014) 267–277.

[29] K.T. Ho, K.C. Chua, E. Klotz, C. Panknin, Stress and rest dynamic myocardial perfusion imaging by evaluation of complete time-attenuation curves with dual-source CT, JACC Cardiovasc. Imaging 3 (2010) 811–820.

[30] J.L. Wichmann, F.G. Meinel, U.J. Schoepf, A. Varga-Szemes, G. Muscogiuri, P.M. Cannao, et al., Semiautomated global quantification of left ventricular myocardial perfusion at stress dynamic CT: diagnostic accuracy for detection of territorial myocardial perfusion deficits compared to visual assessment, Acad. Radiol. 23 (2016) 429–437.